

# Eso-SPONGE®

Endoluminal Vacuum Therapy for the treatment of anastomosis insufficiency  
in the upper GI tract



Aesculap Closure Technologies

# Eso-SPONGE®

## Endoluminal Vacuum Therapy for the treatment of anastomosis insufficiency in the upper GI tract

Anastomotic leakages or other defects in the upper gastrointestinal tract can have serious consequences for the affected patients. Different parameters, like the size, location, time to diagnosis of the lesion, but also the general condition of the patient, have a significant influence on the clinical outcome of the patient.

Often this situation is accompanied by symptoms of sepsis and a significant morbidity rate with corresponding substantial mortality rate.

For this reason the treatment of this clinical situation is often a challenge for the clinician.

Besides surgical examination and the endoscopic stent system, good experiences have been obtained with the Endo-SPONGE® therapy for the lower gastrointestinal tract. Now also the endoluminal vacuum therapy for the upper gastrointestinal is available – Eso-SPONGE®.

For over 5 years we have collected good experiences with this type of therapy. A series of pilot studies and retrospective analysis of different working groups on this subject have demonstrated the particular advantages of endoluminal vacuum therapy.

Eso-SPONGE® represents an innovative therapy concept for the treatment of this problem in the upper gastrointestinal tract, which can contribute significantly to the reduction of morbidity and mortality of patients.




**Prof. Dr. med.**  
**Clemens Schafmayer**  
Universitätsklinik Schleswig-  
Holstein, Campus Kiel



**Prof. Dr. med.**  
**Bodo Schniewind**  
Klinikum Lüneburg

### Advantages of Eso-SPONGE®:

- Continuous drainage, no secretion accumulation
- Infection control
- Debridement, quick cleaning of the wound cavity
- Promotion of granulation tissue ingrowth
- Mechanical reduction of the wound cavity



## Literature concerning vacuum therapy in the upper gastrointestinal tract

Lead author / clinic	Number of patients [n]	Method of application*	Suction amount	Average number of sponge changes***	Vacuum therapy success rate % (x/y)
N. Heits, Universitätsklinikum Schleswig-Holstein, Campus Kiel. <sup>1</sup>	10	i.c.	75-200 mmHg	5.4 [2-12]	90 % (9/10)
H. Lenzen, Medizinische Hochschule Hannover. <sup>2</sup>	3	i.c. / i.l.	–	7 [5-12]	100 % (3/3)
B. Schniewind, Universitätsklinikum Schleswig-Holstein, Campus Kiel. <sup>3</sup>	17	i.c.	70-80 mmHg	–	–
M. Bludau, Uniklinik Köln. <sup>4</sup>	14	i.c. / i.l.	100 mmHg	3.9 [1-9]	86 % (12/14)
M. Brangewitz, Medizinische Hochschule Hannover. <sup>5</sup>	32	i.c. / i.l.	125 mmHg	7 [5-28]	84.4 % (27/32)
T. Schorsch, Katholisches Marienkrankenhaus Hamburg. <sup>6</sup>	24	i.c. / i.l.	125 mmHg	2 [2-12]	95 % (23/24)
F. Kuehn, Universitätsmedizin Rostock. <sup>7</sup>	9	i.c. / i.l.	125 mmHg	6 [1-13]	89 % (8/9)
G. Loske, Katholisches Marienkrankenhaus, Hamburg. <sup>8</sup>	14	i.c. / i.l.	125 mmHg	4 [1-10]	100 % (13/14)**
R. Weidenhagen, Ludwig-Maximilian-Universität München, Campus Großhadern. <sup>9</sup>	6	i.c.	low vacuum wound drainage system	10 [5-10]	100 % (6/6)
M. Ahrens, Universitätsklinikum Schleswig-Holstein, Campus Kiel. <sup>10</sup>	5	i.c.	70-80 mmHg	9 [8-12]	100 % (5/5)
J. Wedemeyer, Medizinische Hochschule Hannover. <sup>11</sup>	8	i.c.	125 mmHg	7 [5-14]	88 % (7/8)

\* i.c. = intracavitary, i.l. = intraluminal

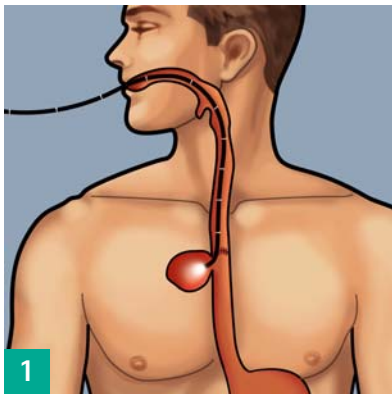
\*\* 1 patient. died due to colitis

\*\*\* [min. - max.]

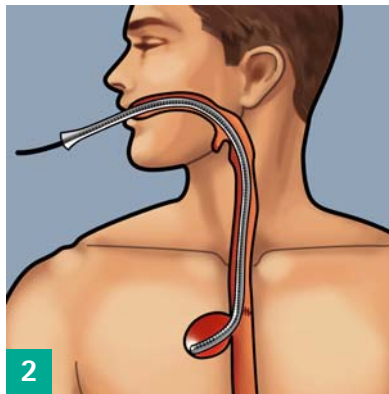
# Eso-SPONGE®

Endoluminal Vacuum Therapy for the treatment of anastomosis insufficiency  
in the upper GI tract

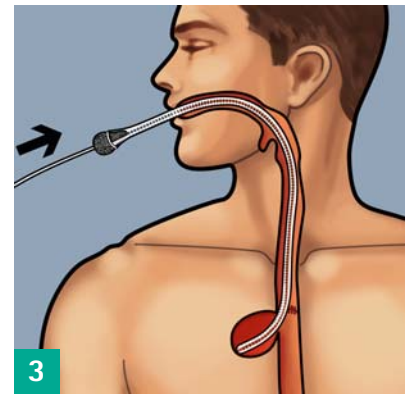
## Therapy procedure



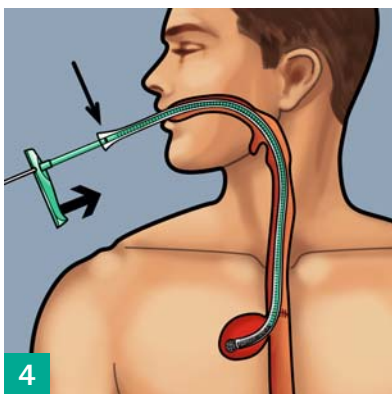
Before use:  
Investigate and measure the wound cavity with a flexible endoscope.



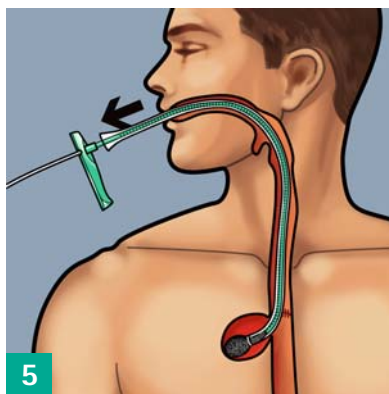
Introduce the overtube under visual control into the insufficiency hole. The endoscope can be used as a guide rail here.



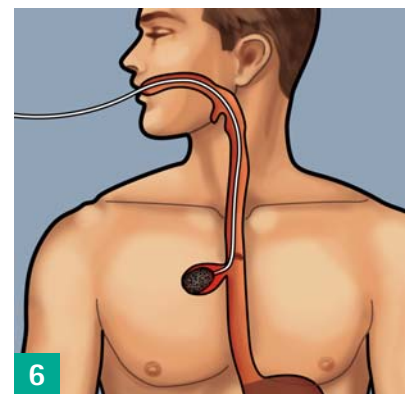
Cover the appropriate, tailored Eso-SPONGE® with sterile hydrogel (glycerol based) and introduce it into the overtube.



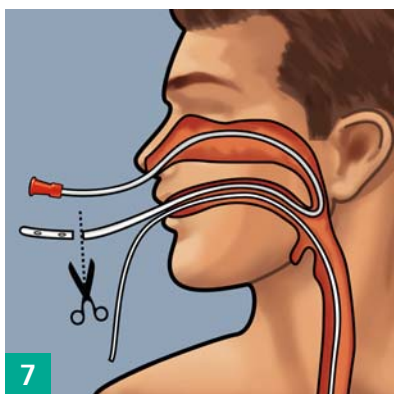
Push the Eso-SPONGE® to the mark with the pusher. The sponge is now at the end of the overtube.



Hold the pusher in place and pull the overtube out as far as the handle of the pusher. The sponge will unfold in the insufficiency hole; the overtube and pusher can be removed together.

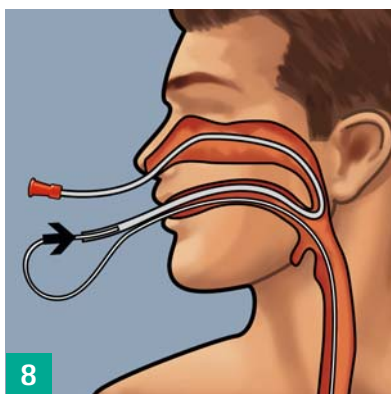


Endoscopic position control of the sponge and appropriate correction by means of endoscopic grasping forceps.

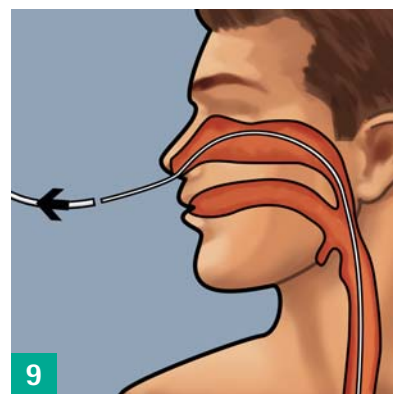


#### Transnasal channelling:

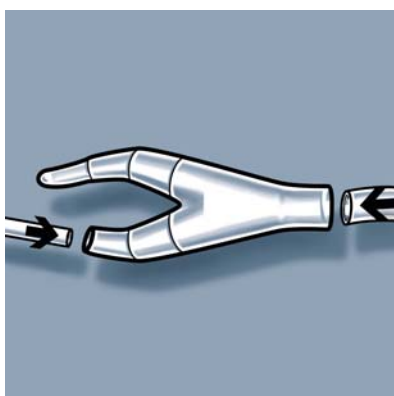
Insert stomach tube CH 16 (not included in the set) through the nose and bring it out through the mouth. Cut off the atraumatic tip.



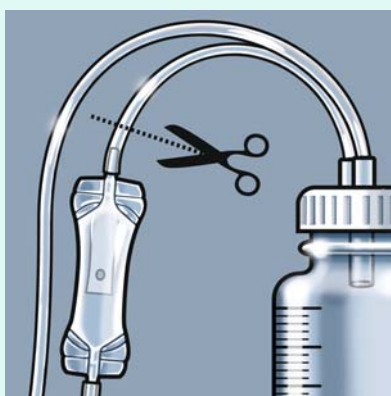
Connect the drain with the stomach tube outside the mouth. Pull the stomach tube together with the drain back through the nose.



The drain is now transnasally channelled.

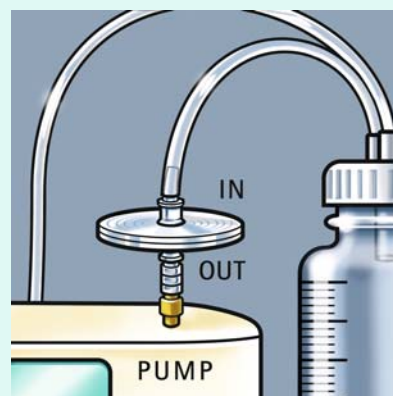


Connect the drain by means of the y-piece to the hose of an adjustable, medical pump with sufficient suction performance.\* Activate the pump, where necessary keeping endoscopic visual control of the sponge.



#### When using the MV 1 pump (MTG Germany):

Cut off the secret valve from the secretion cylinder hose.



Connect the filters using a Luer Lock to the pump and attach the cylinder hose to the filter.

\* Use an adjustable, medical pump with a suction of between 50 and a maximum of 125 mmHg. Regular checking of the system is mandatory. The system must be **changed every 48-72 hours** and, where appropriate, a new sponge inserted.

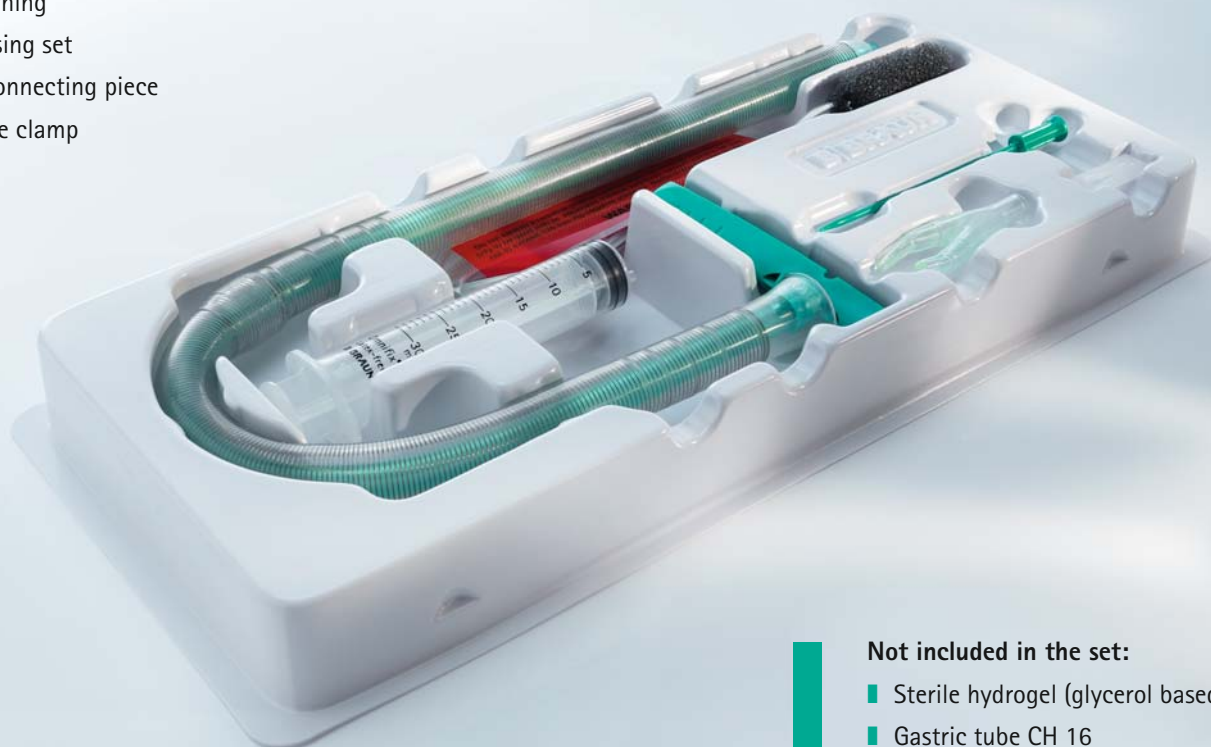# Eso-SPONGE®

Endoluminal Vacuum Therapy for the treatment of anastomosis insufficiency  
in the upper GI tract

## Product and ordering information

### Treatment set:

- Overtube (2 sizes available)
- Pusher
- Eso-SPONGE®
- Warning
- Rinsing set
- Y-connecting piece
- Slide clamp



### Not included in the set:

- Sterile hydrogel (glycerol based)
- Gastric tube CH 16
- Adjustable, medical pump for vacuum treatment (product information MV 1 pump see brochure supplements)

Item no.	Name	Diameter overtube	Content of VE
5526550	Eso-SPONGE® size 1	Inner: 13 mm Outer: 17 mm	1 intervention set
5526540	Eso-SPONGE® size 2	Inner: 15 mm Outer: 19 mm	1 intervention set



## References

- 1 Heits N, Stapel L, Reichert B, Schafmayer C, Schniewind B, Becker T, Hampe J, Egberts JH. Endoscopic Endoluminal Vacuum Therapy in Esophageal Perforation. *Ann Thorac Surg*. 2014 Mar;97(3):1029-35.
- 2 Lenzen H, Negm AA, Erichsen TJ, Manns MP, Wedemeyer J, Lankisch TO. Successful treatment of cervical esophageal leakage by endoscopic-vacuum assisted closure therapy. *World J Gastrointest Endosc*. 2013 Jul 16;5(7):340-5.
- 3 Schniewind B, Schafmayer C, Voehrs G, Egberts J, von Schoenfels W, Rose T, Kurdow R, Arlt A, Ellrichmann M, Jürgensen C, Schreiber S, Becker T, Hampe J. Endoscopic endoluminal vacuum therapy is superior to other regimens in managing anastomotic leakage after esophagectomy: a comparative retrospective study. *Surg Endosc*. 2013 Oct;27(10):3883-90.
- 4 Bludau M, Hölscher AH, Herbold T, Leers JM, Gutschow C, Fuchs H, Schröder W. Management of upper intestinal leaks using an endoscopic vacuum-assisted closure system (E-VAC). *Surg Endosc*. 2014 Mar;28(3):896-901.
- 5 Brangewitz M, Voigtländer T, Helfritz FA, Lankisch TO, Winkler M, Klempnauer J, Manns MP, Schneider AS, Wedemeyer J. Endoscopic closure of esophageal intrathoracic leaks: stent versus endoscopic vacuum-assisted closure, a retrospective analysis. *Endoscopy*. 2013 Jun;45(6):433-8.
- 6 Schorsch T, Müller C, Loske G. Endoscopic vacuum therapy of anastomotic leakage and iatrogenic perforation in the esophagus. *Surg Endosc*. 2013 Jun;27(6):2040-5.
- 7 Kuehn F, Schiffmann L, Rau BM, Klar E. Surgical endoscopic vacuum therapy for anastomotic leakage and perforation of the upper gastrointestinal tract. *J Gastrointest Surg*. 2012 Nov;16(11):2145-50.
- 8 Loske G, Schorsch T, Müller C. Intraluminal and intracavitary vacuum therapy for esophageal leakage: a new endoscopic minimally invasive approach. *Endoscopy*. 2011 Jun;43(6):540-4.
- 9 Weidenhagen R, Hartl WH, Gruetzner KU, Eichhorn ME, Spelsberg F, Jauch KW. Anastomotic leakage after esophageal resection: new treatment options by endoluminal vacuum therapy. *Ann Thorac Surg*. 2010 Nov;90(5):1674-81.
- 10 Ahrens M, Schulte T, Egberts J, Schafmayer C, Hampe J, Fritscher-Ravens A, Broering DC, Schniewind B. Drainage of esophageal leakage using endoscopic vacuum therapy: a prospective pilot study. *Endoscopy*. 2010 Sep;42(9):693-8.
- 11 Wedemeyer J, Brangewitz M, Kubicka S, Jackobs S, Winkler M, Neipp M, Klempnauer J, Manns MP, Schneider AS. Management of major postsurgical gastroesophageal intrathoracic leaks with an endoscopic vacuum-assisted closure system. *Gastrointest Endosc*. 2010 Feb;71(2):382-6.



B. Braun Surgical, S.A. | Carretera de Terrassa, 121 | 08191 Rubí | Spain  
Phone +34 93 586 6200 | Fax +34 93 699 6330 | [www.bbraun.com](http://www.bbraun.com)

Aesculap AG | Am Aesculap-Platz | 78532 Tuttlingen | Germany  
Phone +49 7461 95-0 | Fax +49 7461 95-2600 | [www.aesculap.com](http://www.aesculap.com)

Aesculap – a B. Braun company

The product trademarks 'Endo-SPONGE' and 'Eso-SPONGE' are a registered trademarks of Aesculap AG.

Subject to technical changes. All rights reserved.  
This brochure may only be used for the exclusive purpose of obtaining information about our products. Reproduction in any form partial or otherwise is not permitted.

Brochure No. B26902

1014/x/1